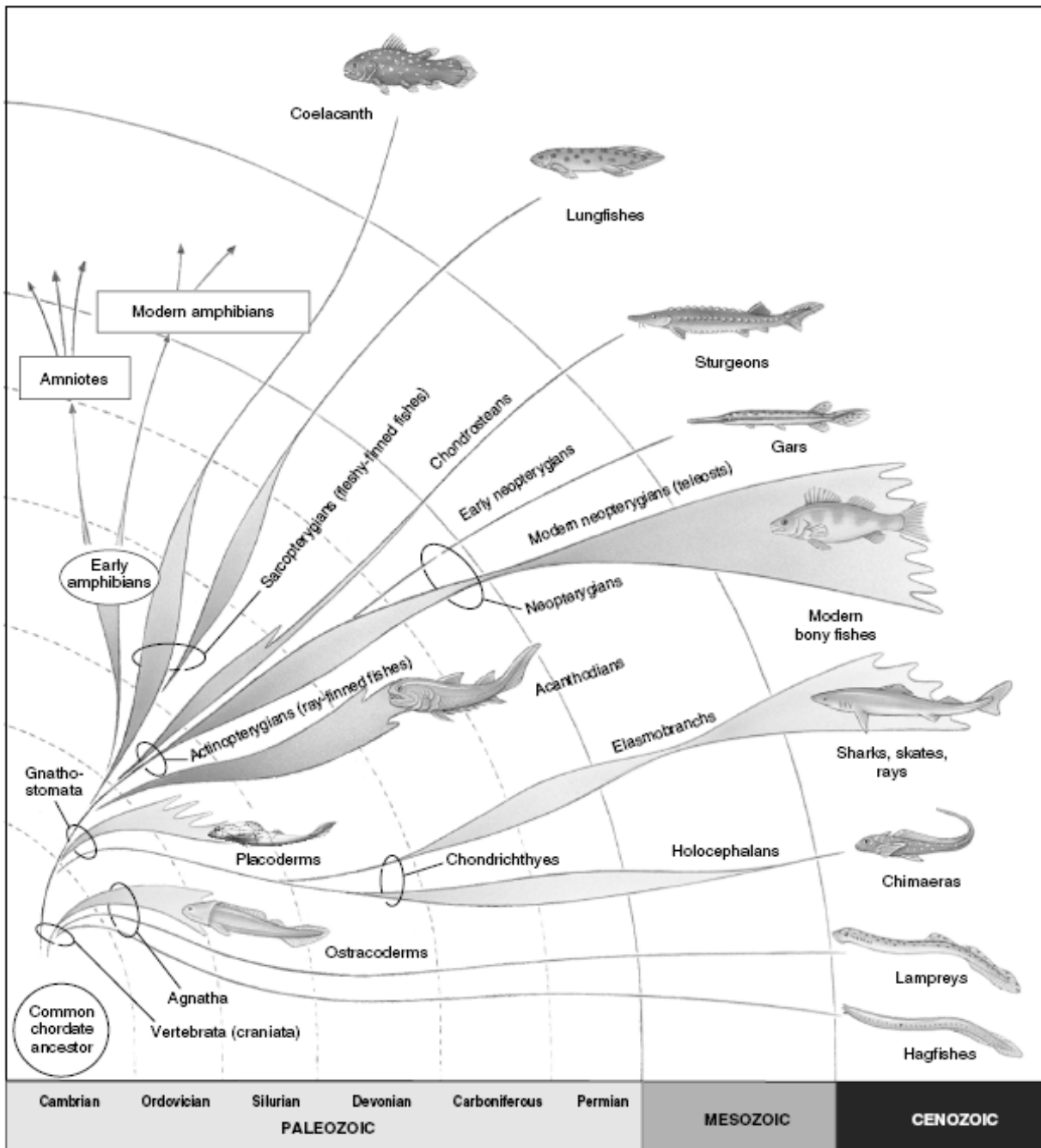

2- رده دهان گردان (Cyclostomata):

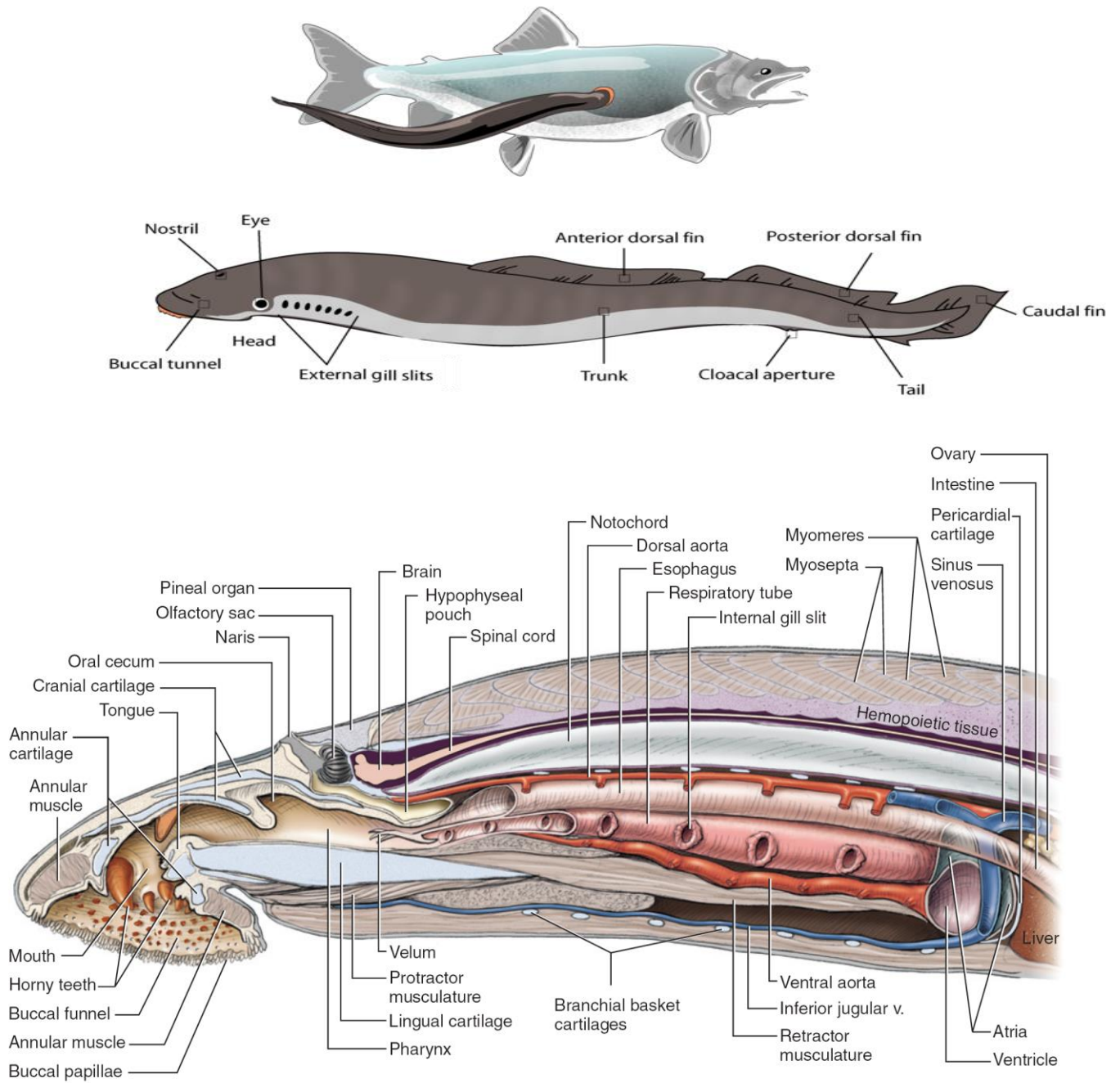
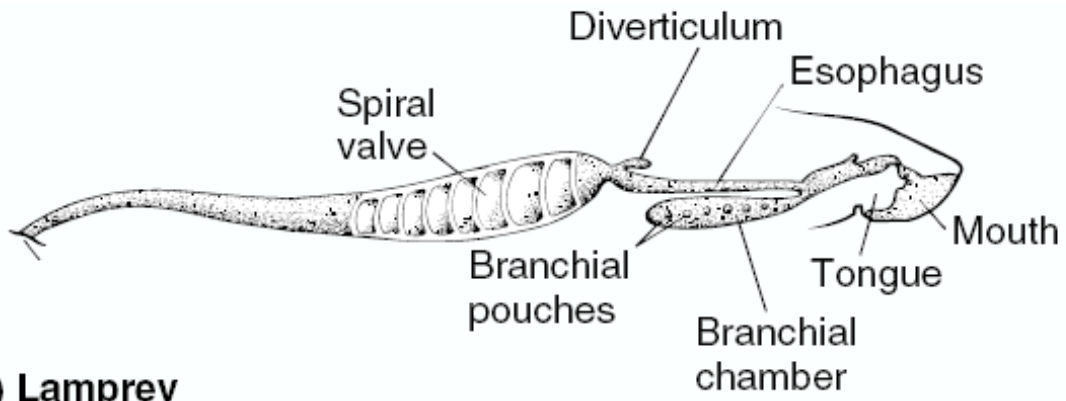
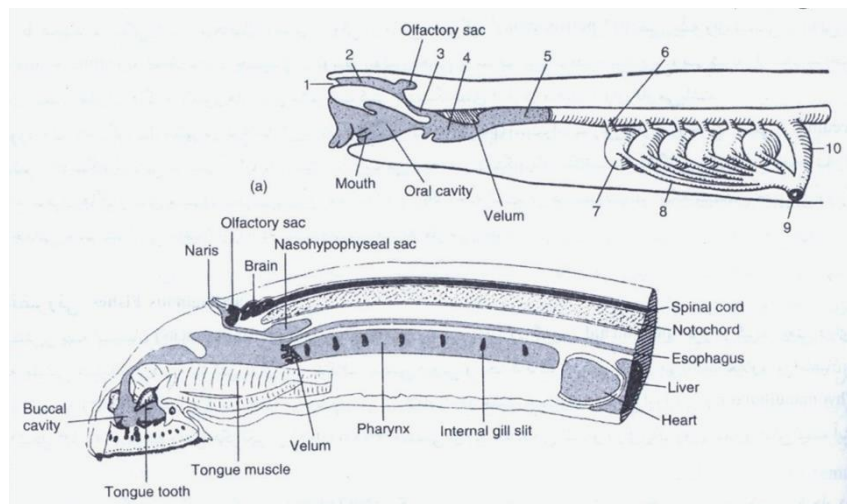


FIGURE 2.8 Schematic sagittal section through head and pharyngeal region of the lamprey. The vessels, esophagus, respiratory tube, and parts of the heart are shown with portions cut away, rather than in sagittal section.

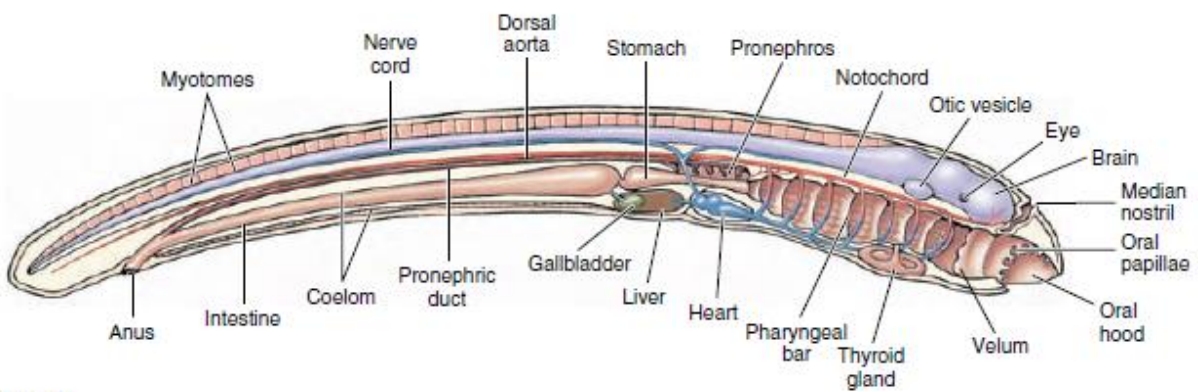


(a) Lamprey

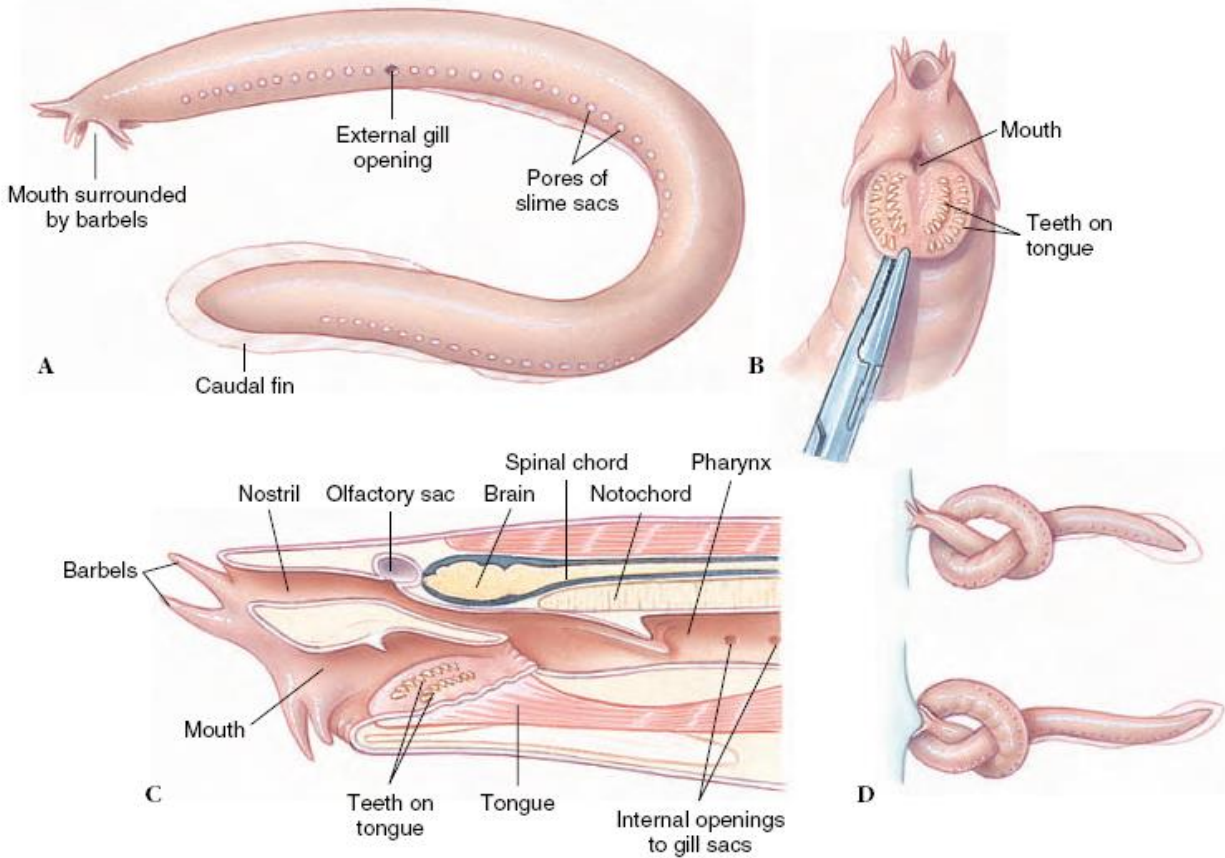
تنفس در لامپری و هاگ فیش



لارو آموست در لامپری

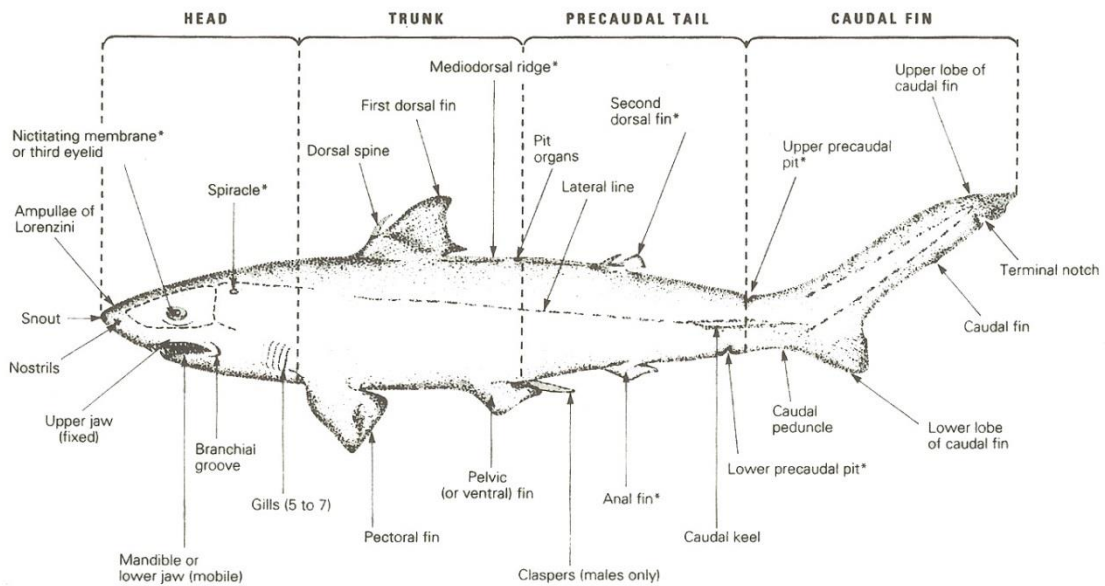


Hagfish: شکل ظاهری، ساختار دهانی، سوراخ بینی

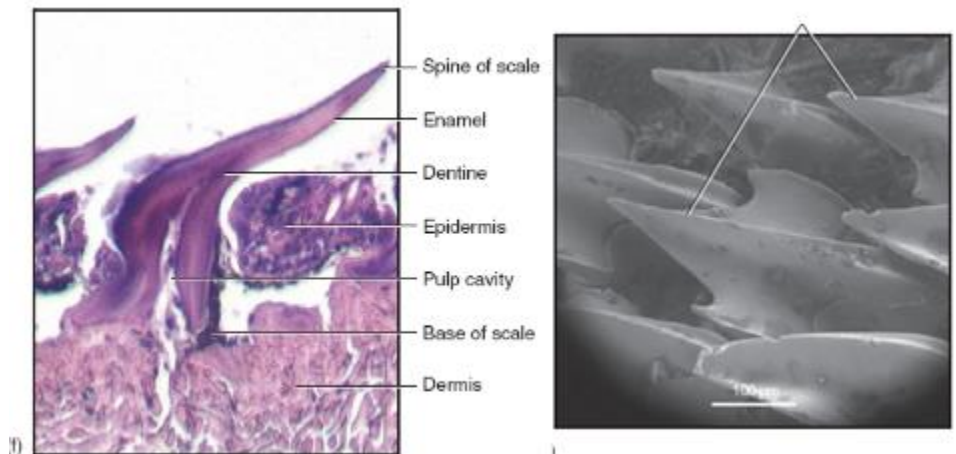


ماهیان غضروفی

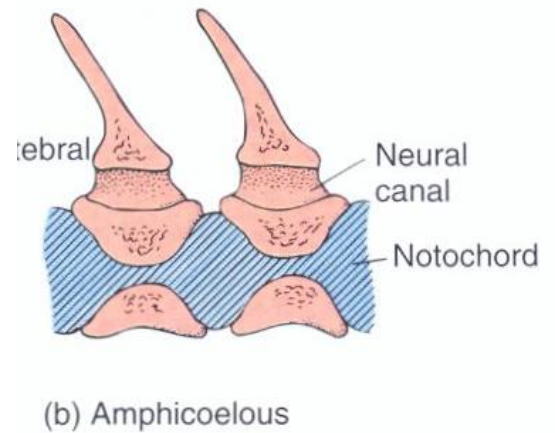
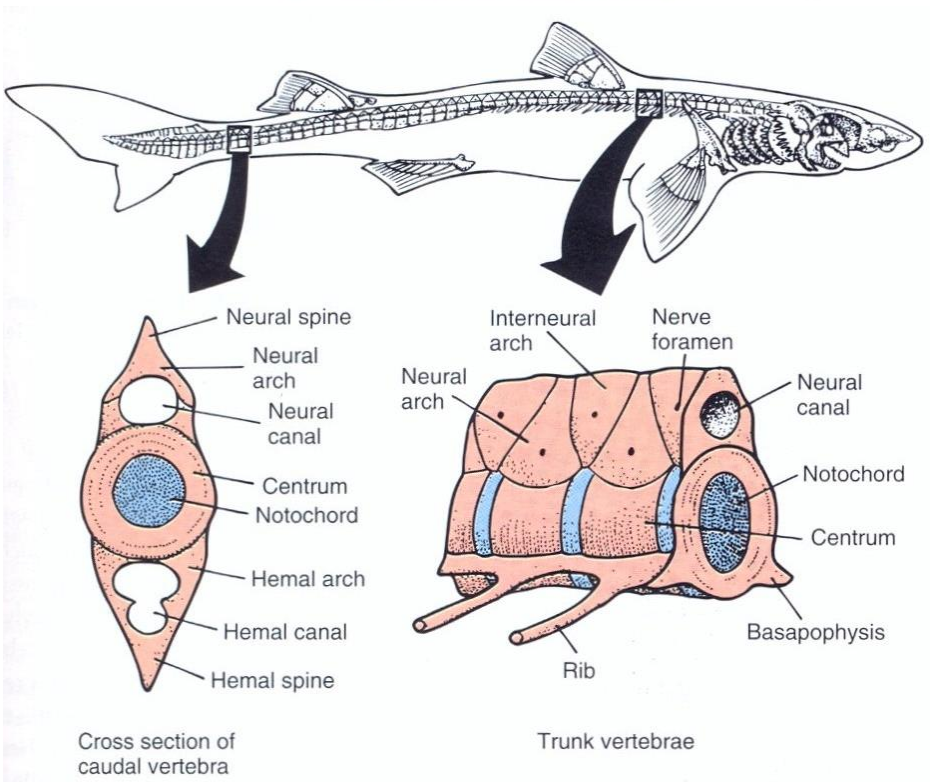
TERMINOLOGIE ANATOMIQUE GÉNÉRALE DU REQUIN.



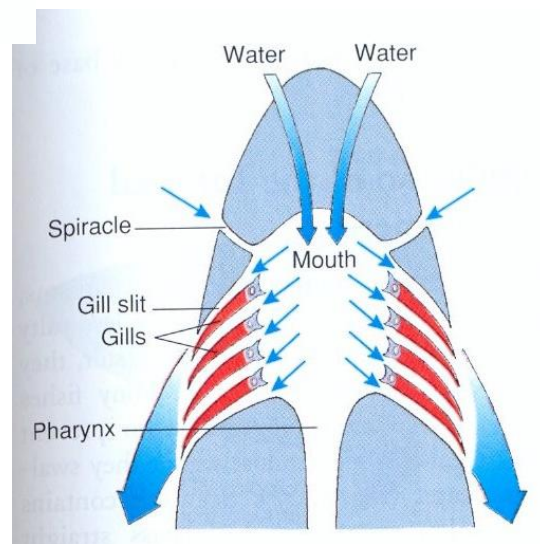
* Organs not found in all sharks

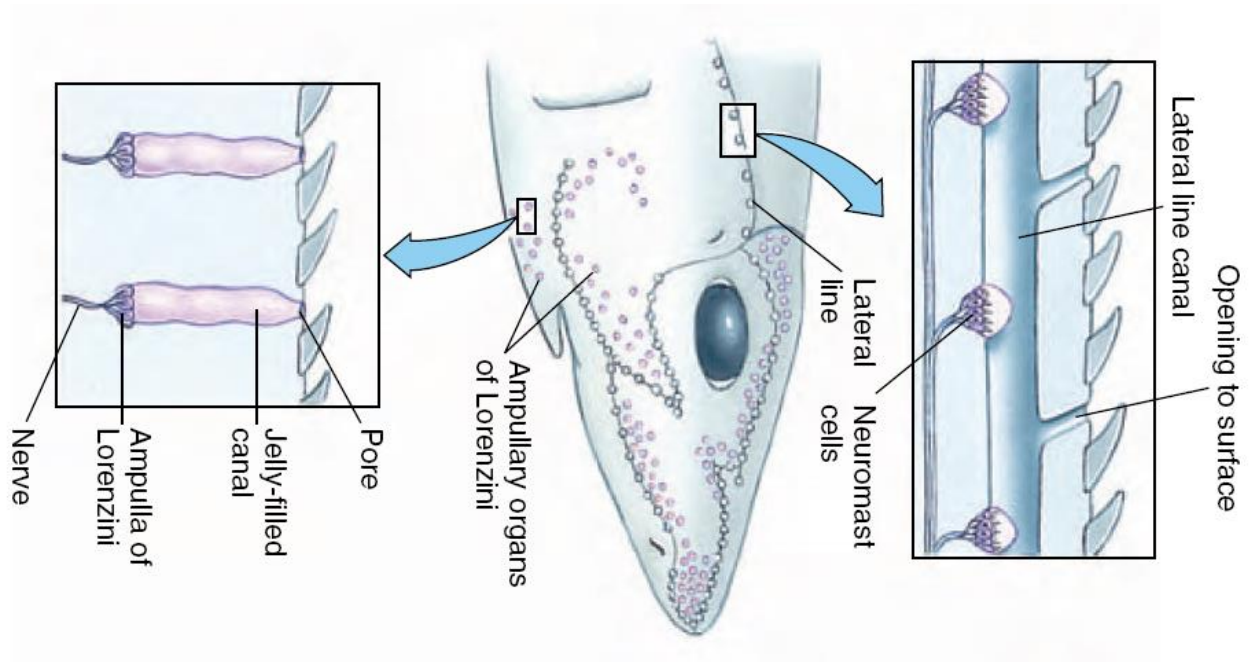


اسکلت تنه

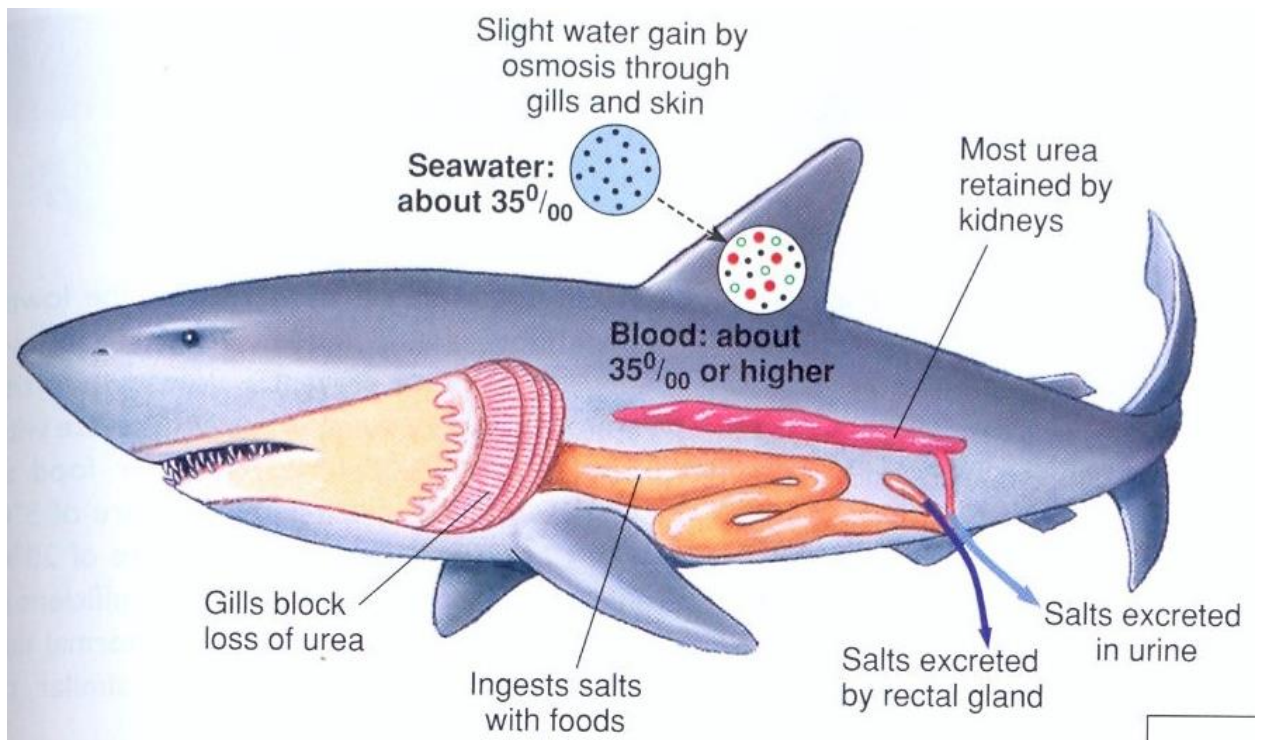


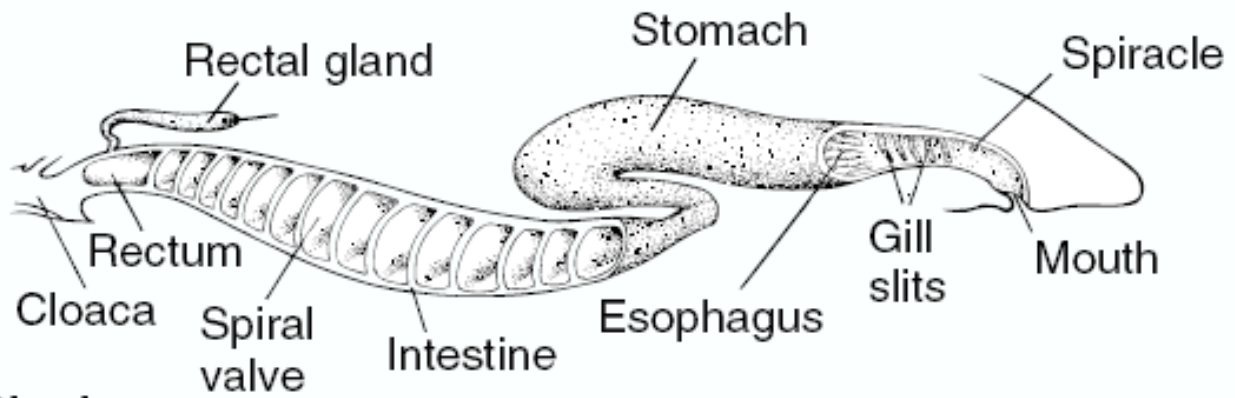
تنفس در کوسه ماهی ها





دستگاه دفعی: کلیه های مزونفروس (اپیستو نفریک)، غده rectal ، آبشش ها و پوست بدن





(b) Shark

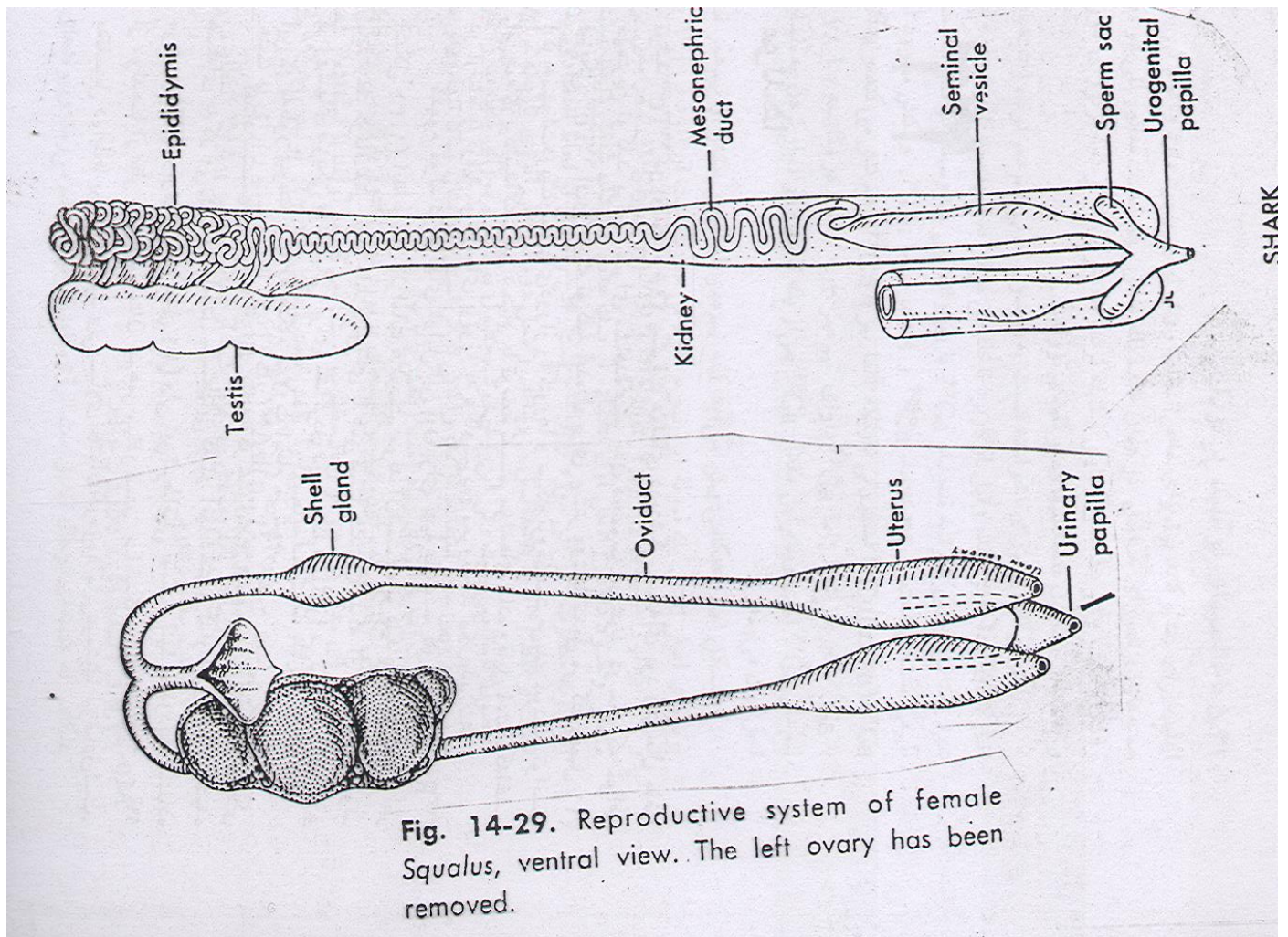




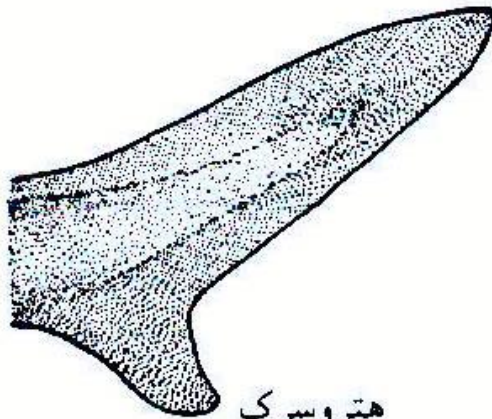
Fig. 14-29. Reproductive system of female *Squalus*, ventral view. The left ovary has been removed.



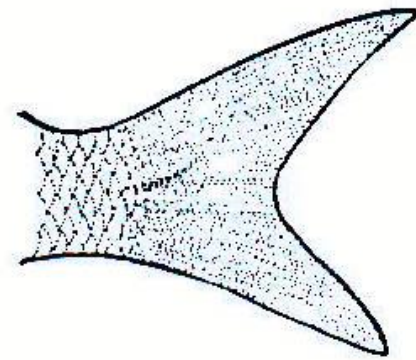
پروتوسرک



دیفی سرک

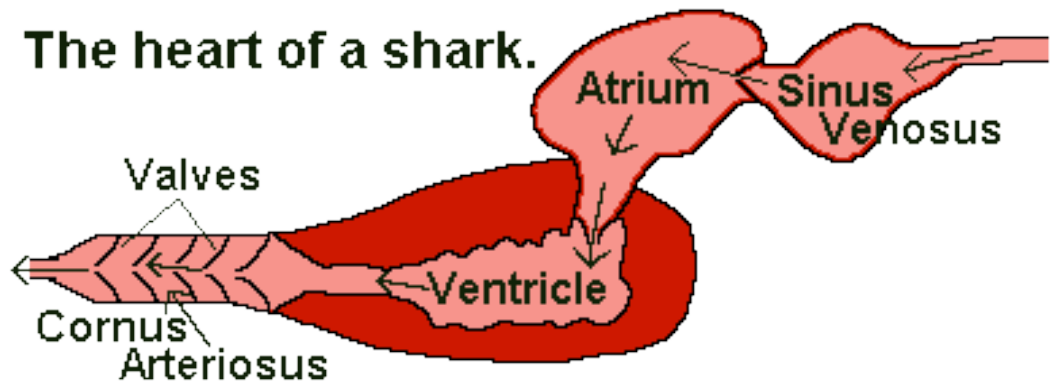


هتروسرک



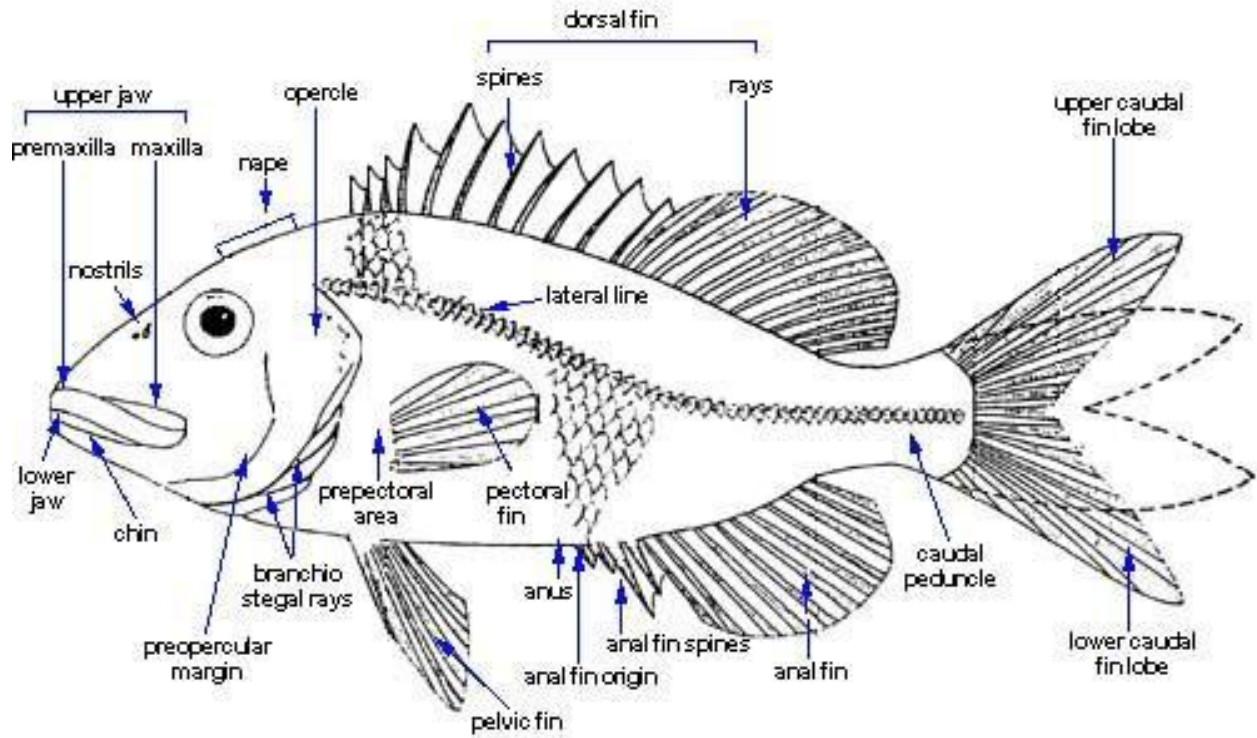
هموسرک

شکل ۲۵-۳ چهار نوع دم در ماهیها.




قلب کوسه ماهی

مورفولوژی خارجی ماهی استخوانی




انواع فلس در ماهیان استخوانی



Ganoid scales
(nonteleost bony fishes)

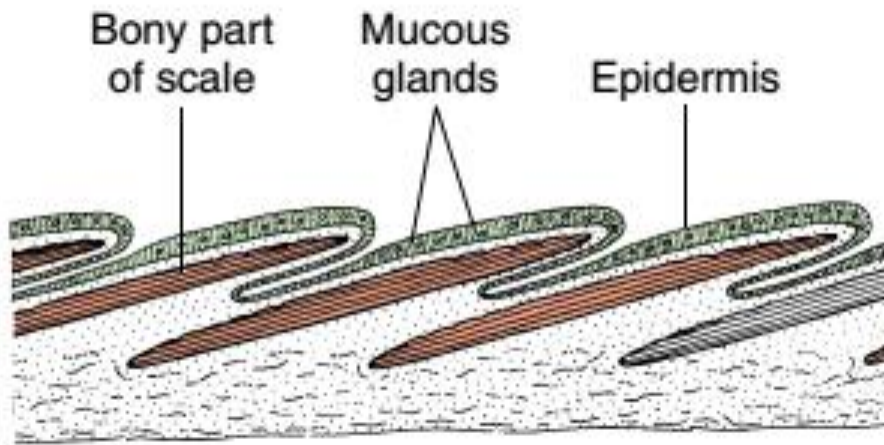


Cycloid scales
(teleost fishes)



Ctenoid scales
(teleost fishes)

فلس ها در ماهیان استخوانی درون ساختار پوست



دستگاه های ماهی استخوانی

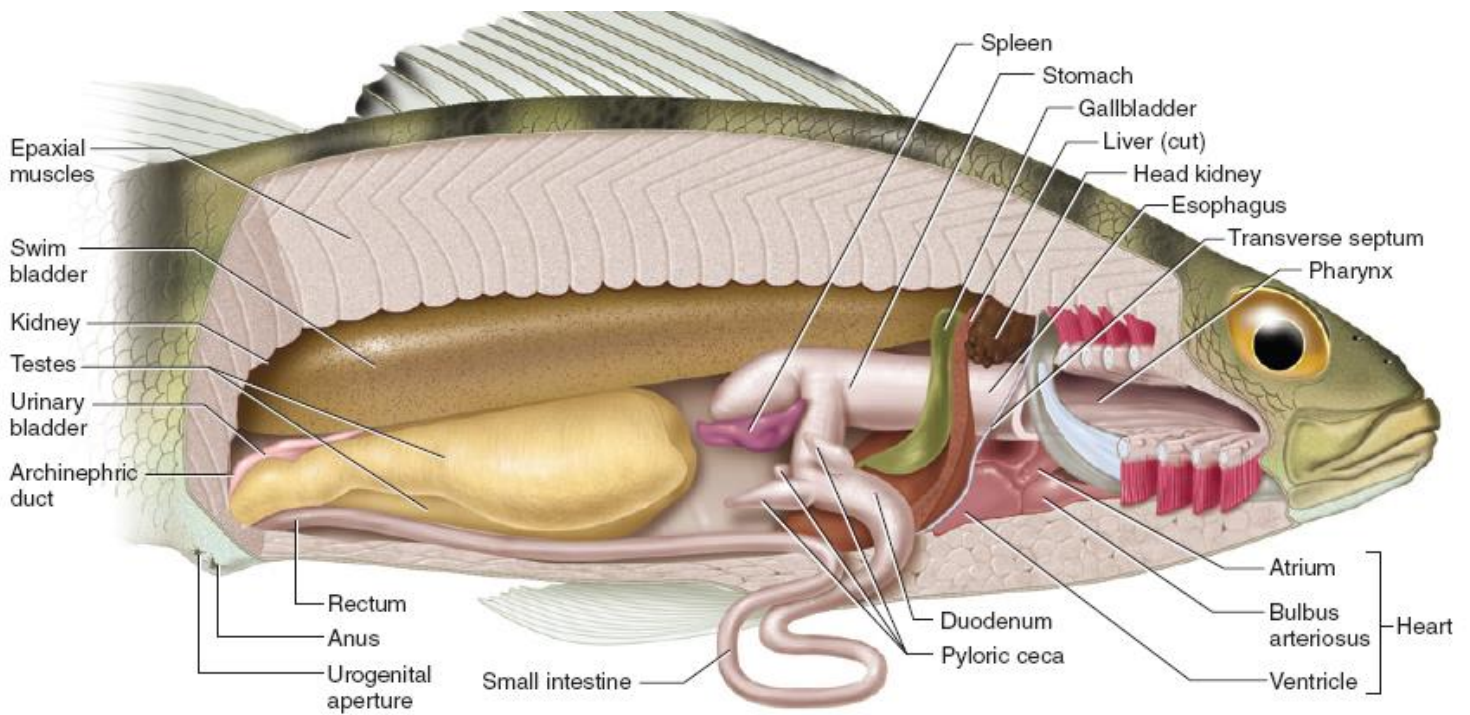
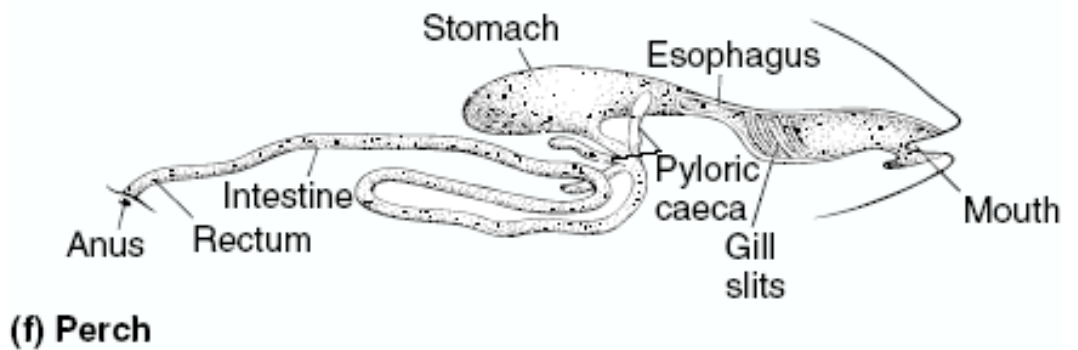


FIGURE 4.8 Cutaway view of the male perch in right lateral view, to reveal structures of the pharynx and pleuroperitoneal cavity.



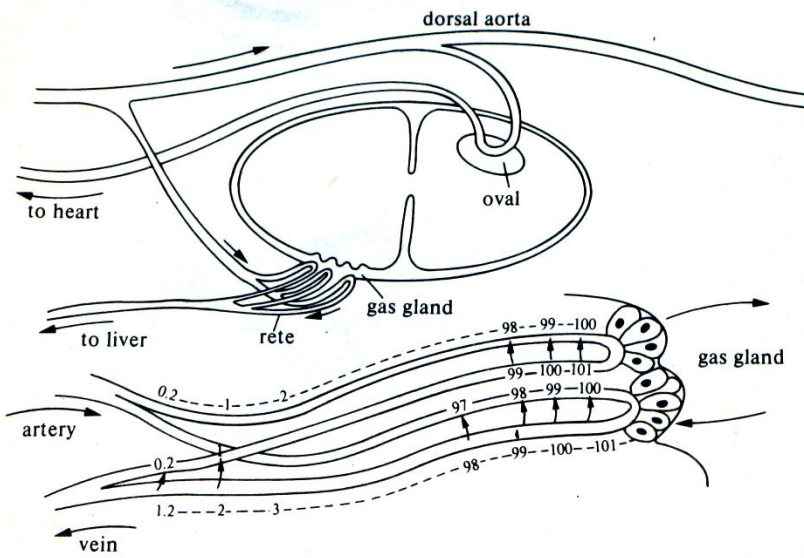
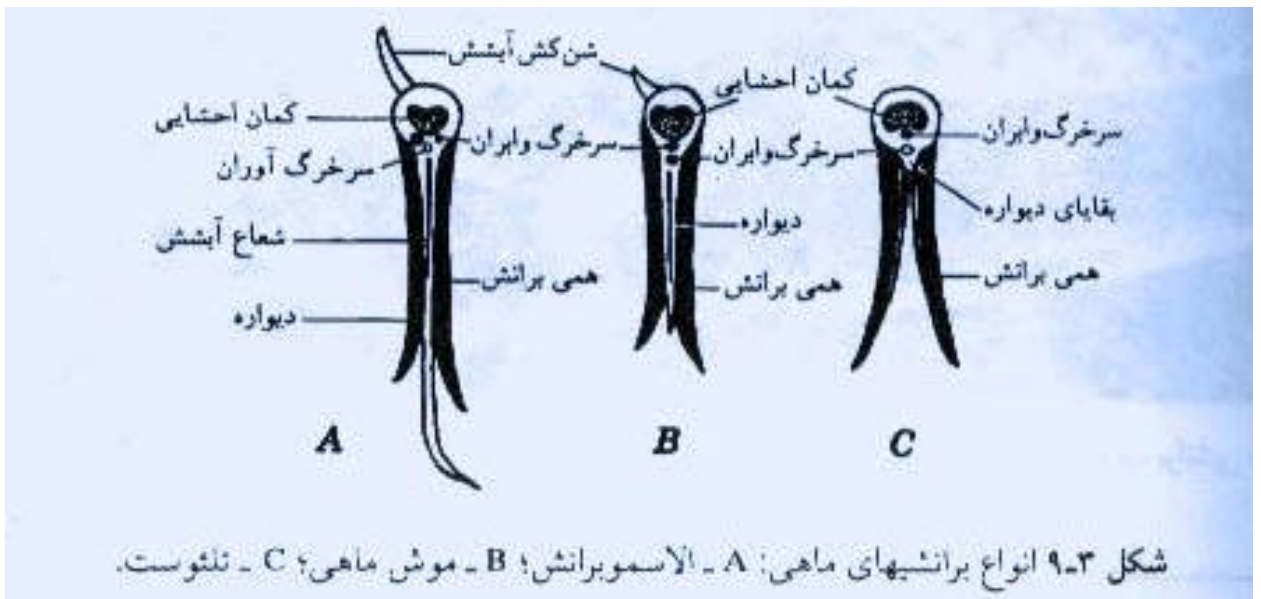


FIG. 9.17. Diagram of the circulation of the swim-bladder and the countercurrent multiplier system. Blood may reach the swim-bladder through the rete mirabile (supplying the gas gland) or by a vessel to the oval (where fine blood vessels can absorb gases). As the gas gland produces lactic acid, the oxygen tension increases in the venous capillary and gas diffuses to the arterial capillary. (After Schmidt-Nielsen 1979.)



آیشش در ماهیان استخوانی

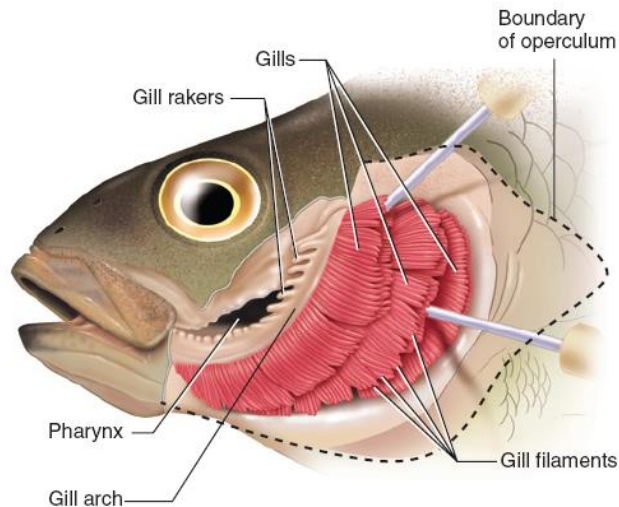
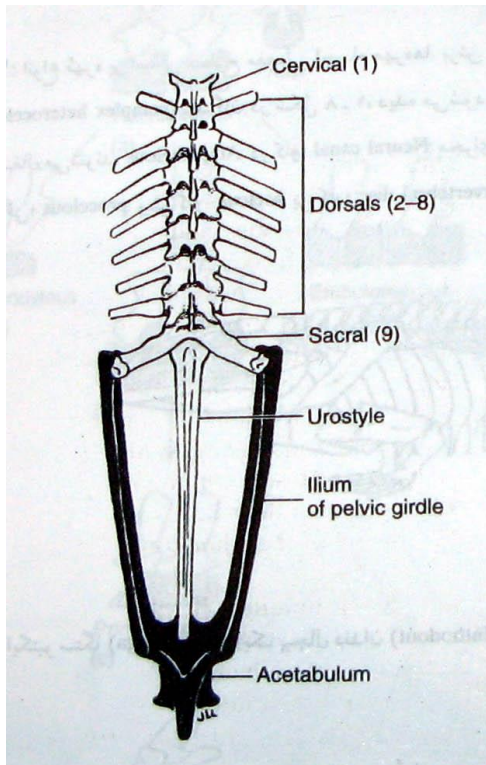
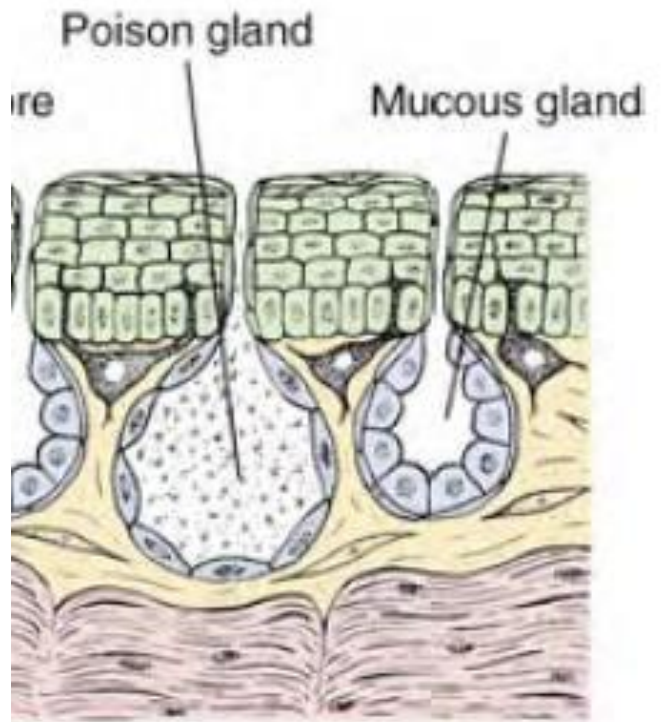
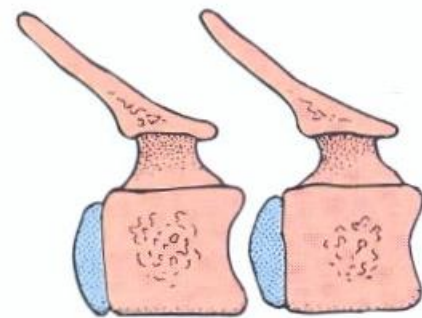


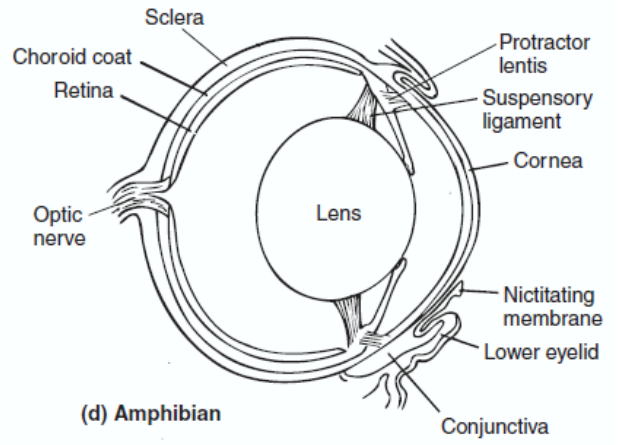
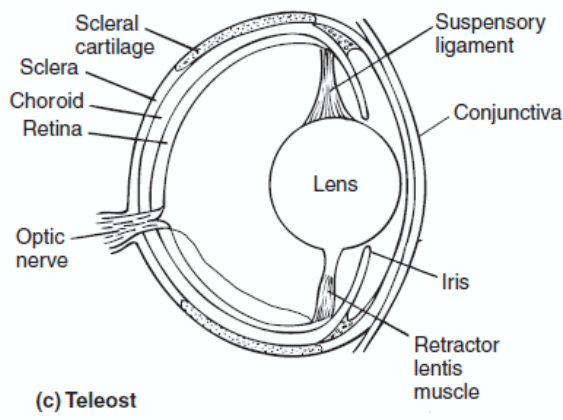
FIGURE 4.5 Gills of the perch in left lateral view.



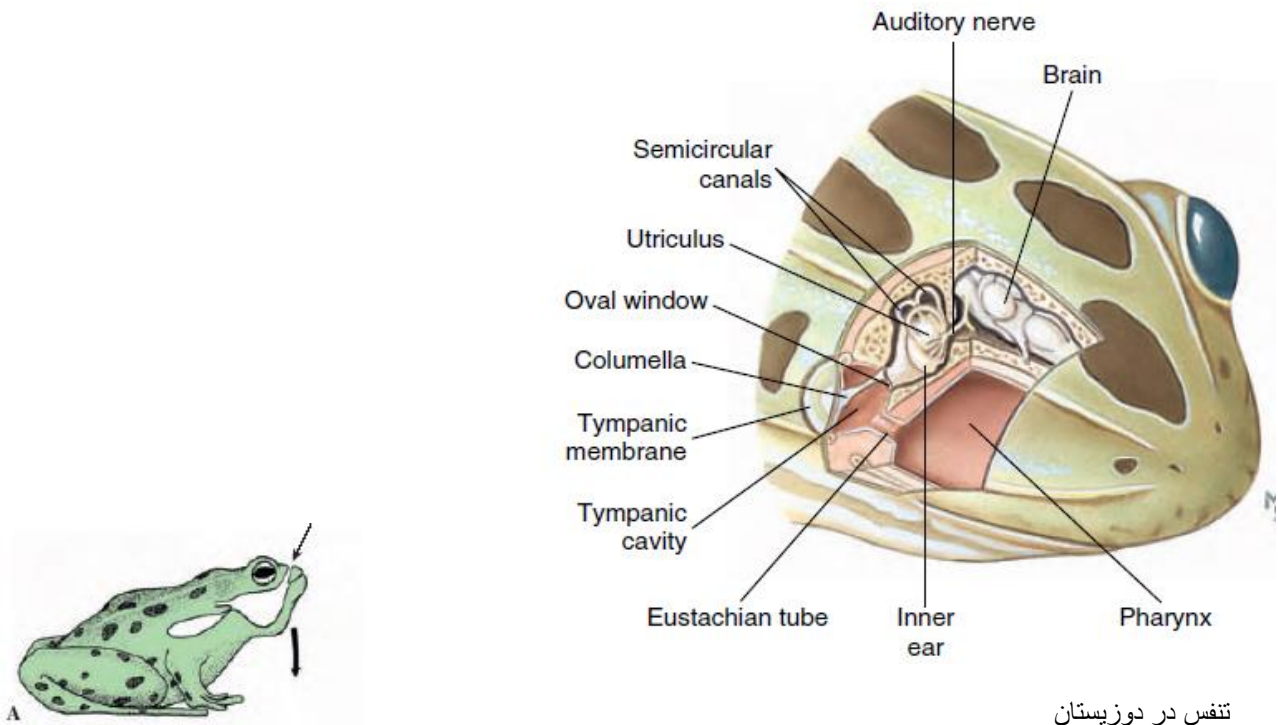
مهره ها در دوزیستان



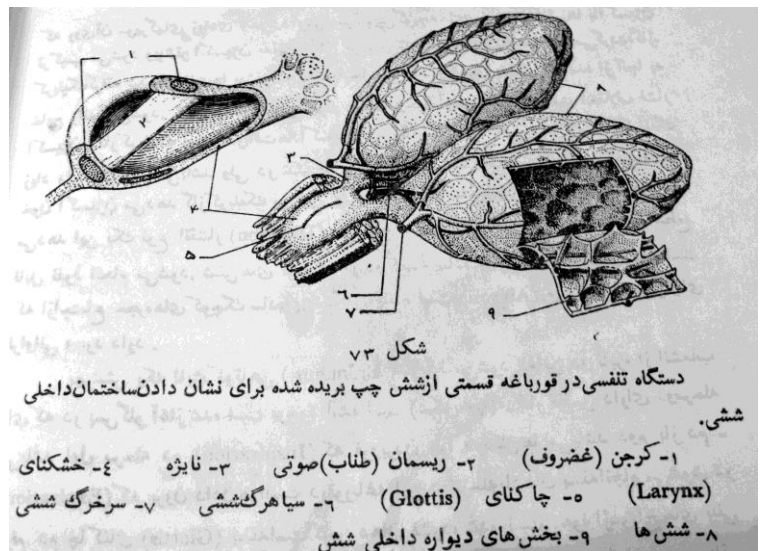
(c) Procoelous



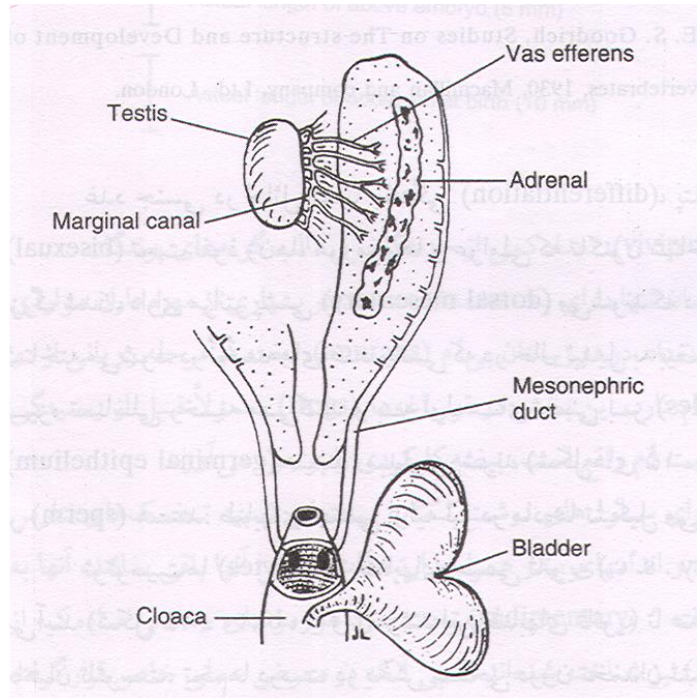
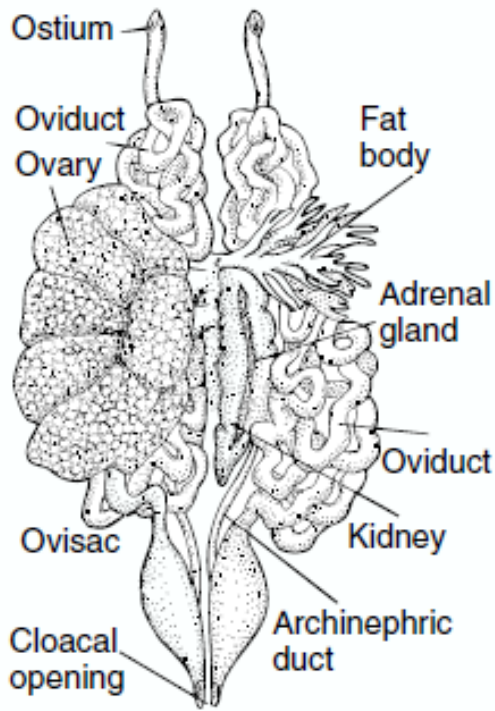
شنوایی در دوزیستان



تنفس در دوزیستان

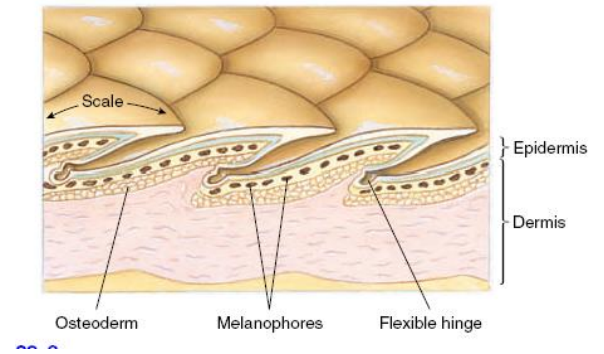
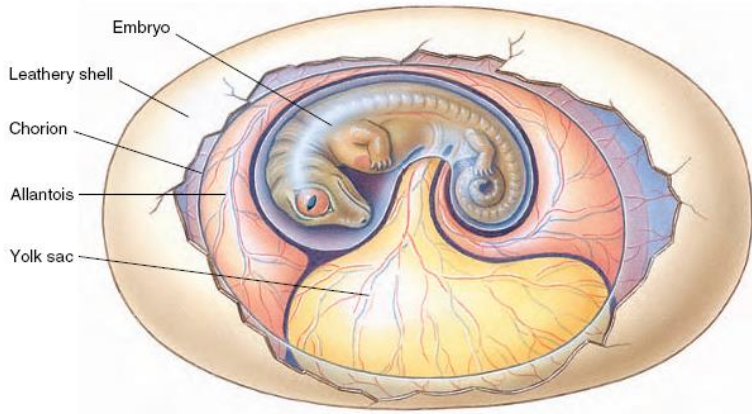


دستگاه تناسلی در قورباغه

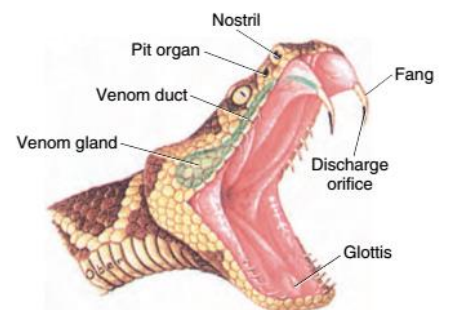


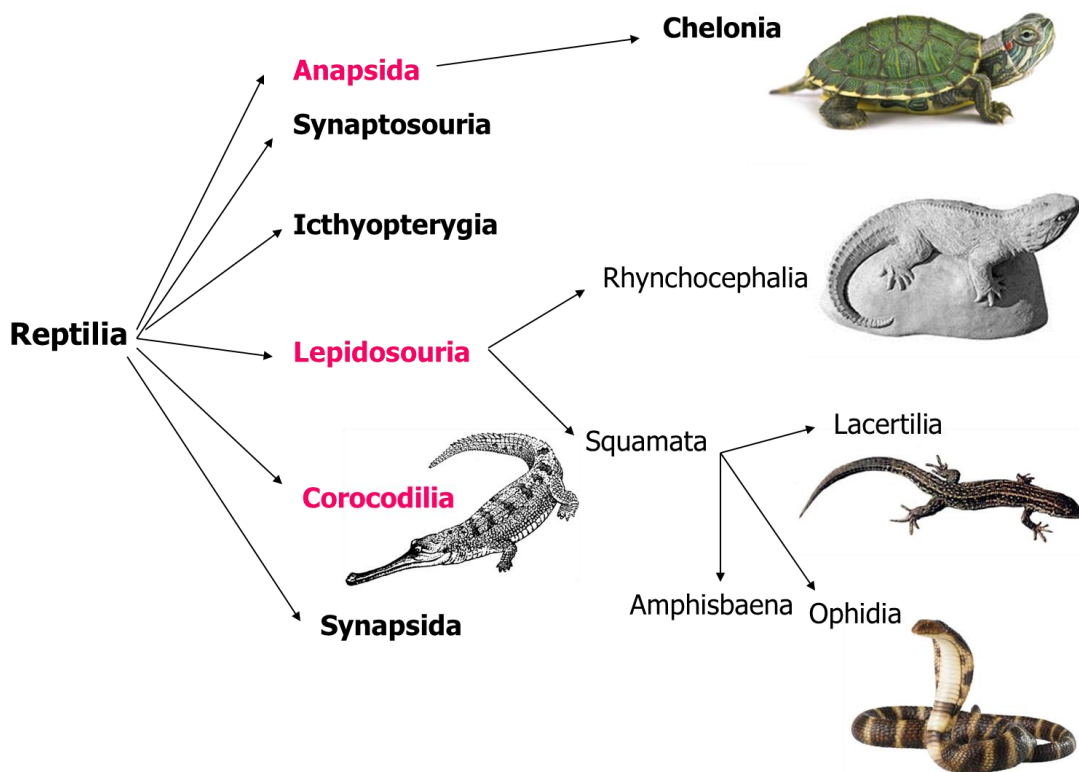
امنیون داران و لایه های جنینی

پوست در خزندگان



غدد سمی در خزندگان





انواع دندان در مارها

